

Minimally Invasive Approach in Surgical Treatment of Tumors of Maxilla

Dikarev A, Porhanov V, Kochergina E, Pavlov I, Kokaev K, Kutsenok M, Paramonova O and Savosin Y

Head and Neck Surgery Department, Research Institute, Regional Clinical Hospital, 167, Maya St. Krasnodar, Krasnodar Region-350086, Russia

Corresponding author: Dikarev A, Head and Neck Surgery Department, Research Institute, Regional Clinical Hospital, 167, Maya St. Krasnodar, Krasnodar Region-350086, Russia, Tel: 007(918)340-02-00; E-mail: asdikarev@gmail.com

Rec date: Mar 10, 2016; **Acc date:** Apr 02, 2016; **Pub date:** Apr 04, 2016

Copyright: © 2016 Dikarev A, et al. This is an open-access article distributed under the terms of the Creative Commons Attribution License, which permits unrestricted use, distribution, and reproduction in any medium, provided the original author and source are credited.

Abstract

Objective: By benign and malignant tumors of the maxillary sinus and maxilla there is frequently a need to perform a total maxillectomy. In this article we describe a transconjunctival-transoral approach, which can be evaluated in terms of esthetic result, complications, integrity of the important structures of the midface that provide physiological function and reduce the rehabilitation period.

Study design: We operated seven patients in the time between 2013-2014. Among them were four patients with malignant tumors with preoperative radiology treatment one patient with malignant tumor without preoperative radiology treatment and two patients with benign tumors. All these patients have no recurrence until now.

Methods: The surgical technique is performed in following steps: transconjunctival incision, exposure of the zygomatic bone, low orbital rim and orbital floor through precise dissection of the structures of the low eyelid, intraoral incision, traditional osteotomies with preserving the low orbital rim, lateral canthopexy, skin suturing.

Results: Reduction of the postoperative treatment period and complications, better esthetic results.

Conclusion: Transconjunctival - transoral approach benefits the conventional ones in fast rehabilitation, good esthetic results without facial scars and low eyelid malposition.

Keywords: Malignant tumor; Benign tumor; Maxilla; Maxillary sinus; Atransconjunctival-transoral approach; Maxillectomy

affected structure in this group is maxilla. Specialty of the pathology is a generalized primary neglect of 80-85%. According to medical literature evidence [1-3] there are no distinct gender differences in the morbidity to be observed. Neoplastic process in the maxillary sinus mostly occurs in the patients' group over 50 years old [4]. The most frequent pathology is squamous cell cancer.

In the majority of cases of benign and malignant tumors of the maxilla the predominant method of the treatment appears to be the surgical one [3]. The radicalism of the applied procedure ensures the best prognostic result [3]. One can determine the extent of the resection by the rate of expansion of the neoplastic process. In the cases where the maxillary sinus is involved, the therapy of choice is maxillectomy [4-7].

Lateral rhinotomy [8], Weber-Fergusson [2,9] approach and its modifications constitute the classical approach to the middle zone of facial skeleton [10,11]. The conventional methods mentioned above are transcutaneous with crossing of the superficial muscle-aponeurotic layer and the facial muscles. An outcome of the procedure appears to be the forming of scar tissue in the facial zones of high social significance. Furthermore, frequent complications could be asymmetry of the face, risk of the fistula and dehiscence of the incisional wound, scar tissue malposition on the inferior eyelid.

The report represents our experience on applying the surgical method of tumor resection in the middle zone of the face by means of combined transoral - transconjunctival approach. An extended incision in the face and a structural damage of the superficial muscular - aponeurotic system of the face will be thereby avoided, and the postoperative esthetic defects, among them the malposition of the inferior eyelid, will be minimized.

This minimal invasive approach reduces the period of rehabilitation for the patients' group with tumors of the maxilla and zygomatic - orbital complex.

Aim of the study: the aim of this study is to present a modified method of the total maxillectomy that we are performing frequently in our clinic. Furthermore we attempt to prove that this method provides better esthetic results and reduces complications in comparison to the common ones. Lastly, the hospital could profit from the shorter rehabilitation period through the higher income and the lower clinical cost.

Introduction

In the structure of morbidity the malignant tumors of maxillary sinus constitutes 0.2% to 1.4%. The most frequently

Materials and Methods

Patients

In our clinic in the period of 2013-2014 seven patients have been operated using this minimal invasive approach. Five of them have had malignant tumors of the maxilla (stage T3 - T4), four of which underwent adjuvant radiotherapy. The rest two patients have had benign tumors of the maxilla.

By all the cases CT scans with contrast were used for tumor staging, in accordance to the UICC - 2002 TNM Classification.

Surgical technique

The operation was held under general anesthesia: We used the upper transconjunctival approach (Figure 1). The conjunctiva should be incised 2 mm from the edge of the lower tarsal plate. After finding the middle lamella we carry out a tissue dissection along the above mentioned structure leaving the orbicular muscle and orbital septum anatomically intact. We mobilize the orbicular muscle in the preseptal layer with preserving small branches of ramus zygomaticus of the facial nerve (Figure 2). On the inferior orbital rim the periosteum has to be incised and a subperiosteal dissection of the orbital floor has to be carried out.

On the external surface of the maxilla downwards the lower orbital rim: we sharply cut off the orbicular retaining ligament (Figure 3), orbicular muscle, m. zygomaticus major and minor, m. levator anguli oris, m. levator labii superior. We cut the cantal ligament laterally and expose the surface of the zygomatic bone (Figure 4) and half of the zygomatic arch subperiosteally, cutting off the ligament of the m. masseter throughout 3-4 mm. Afterwards we perform the resection of the tumor.

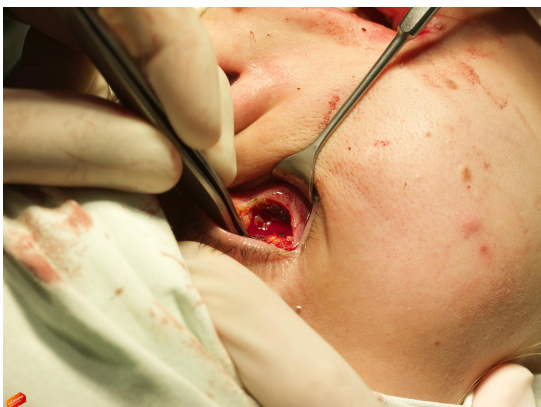

Figure 1: Transconjunctival approach, conjunctiva section, inferior lateral cantal tendon transection.

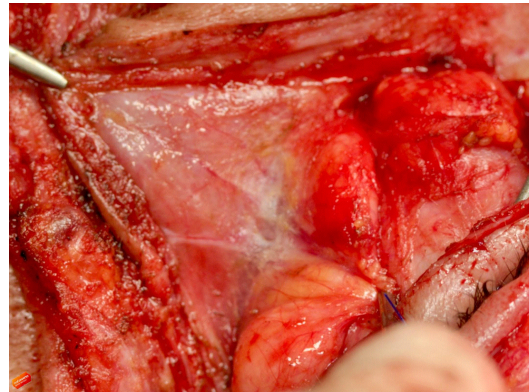


Figure 2: Orbicularis facial nerve motor branches preseptal plane dissection.

We incised oral mucosa along the mucobuccal fold of the maxilla from the maxillary tuber to the level of the first incisor and then downwards. The anterior surface of the maxilla is dissected subperiosteally. Further, the incision is made between central incisors along the hard palate vertically till the level of the soft palate and then horizontally lengthwise till the border of the hard palate in the direction of the maxillary tuber.

We made osteotomies along the nasal process of the maxilla, lacrimal bone, zygomatic bone and the middle line of the hard palate. According to the indications, it is possible to preserve the lower orbital rim in the form of the bridge from the body of the zygomatic bone to the nasal bone (Figure 5). As the last step we perform the detachment of the maxillary tuber from the pterygoid process of the sphenoid bone.

After the removal of the resected specimen (Figure 6) and antiseptic irrigation of the resection zone we perform the standard lower lateral canthopexia. The fixation has to be carried out to the remained lateral part of the cantal ligament or to the lateral orbital rim itself with drill holes.

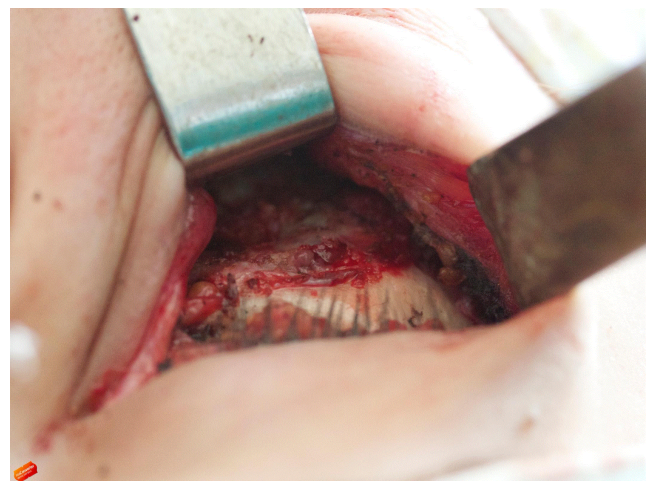


Figure 3: Orbicularis retaining ligament dissection along the external surface of the maxilla.

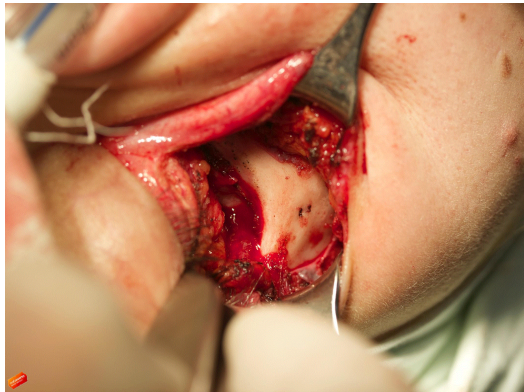

Figure 4: Subperiosteal skeletonization of the external surface of the zygoma.

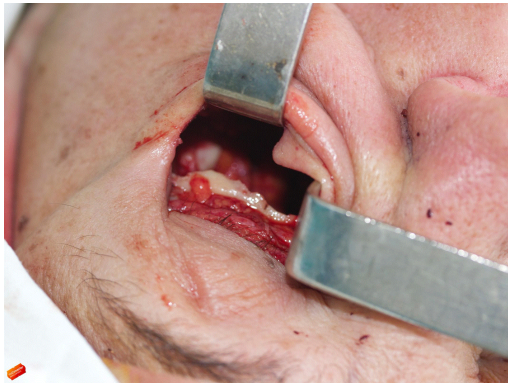

Figure 5: Key point – preserved anterior part of the lower orbital rim.

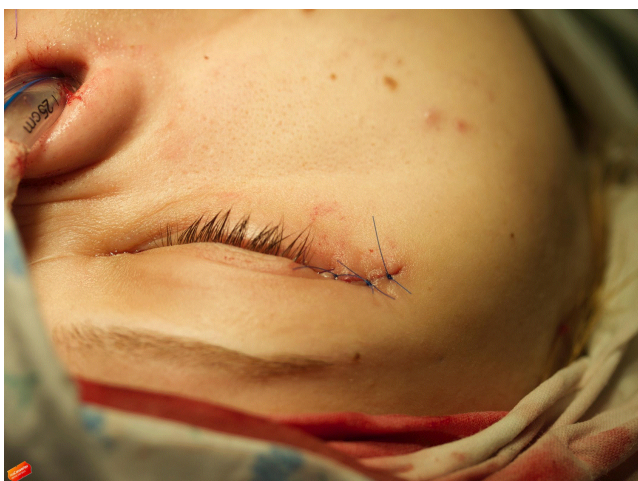

Figure 6: Wound closing – lateral cantal restoration, skin suturing.

In the intra- and postoperative period we prescribed broad-spectrum antibiotics for all the patients.



Figure 7: PreOP: Patient 26 years old, D-s: Mixoma of the maxilla (right side), 4 times relapsing after transoral surgical treatment; PostOP- 18 months.

The postoperative period passed according to the standard without any complications. All the patients left the clinic on the 4th day. By now all the patients are observed without relapsing (Figure 8).

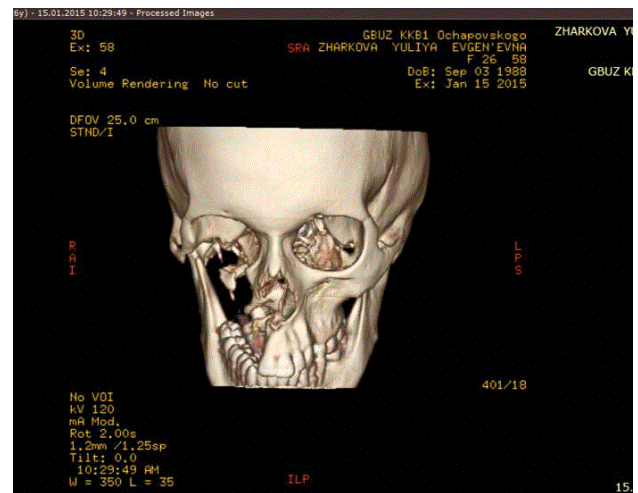


Figure 8: PostOP computer tomography.

Results

The suggested method was used in 7 patients in general: among them were four patients with malignant tumors with preoperative radiology treatment one patient with malignant tumor without preoperative radiology treatment and two patients with benign tumors. Herewith we have achieved a reduction of postoperative treatment period in comparison with patients, by whom were performed equivalent tumor resection by means of classical transcutaneous approaches. All

We sutured skin incision of the lateral eye angle area with interrupted sutures Prolene № 6 (Figure 7), removed on the 3th day. We have placed mattress suture Monocryl № 6 on conjunctiva. We used Levomekol wound salve and gas packing.

patients had to stay in the hospital for an average of 4 days, the sutures could be removed after only 7 days.

Discussion

Traditional approaches as lateral rhinotomy and Weber - Fergusson approach and its modifications are normally used for the total and subtotal maxillectomy by malignant and benign tumors of the maxilla [12] and maxillary sinus. Those approaches provide good visualization, but most of the patients receive adjuvant radiotherapy, that can cause fistulae and dehiscence of the wound in the postoperative period. Furthermore, traditional approaches cause extended facial scars.

Atransconjunctival - transoral approach avoids broad transfacial incisions and gives a surgeon a sufficient visualization of the field with a possibility to perform a precise resection according to the standard of radicalism with intraoperative appropriate control of the margins. The reduction of complications and recovering period compensates the difficulty of the approach. The outcome is followed by good esthetic result without lower eye lid and eye globe malposition.

The major indication of the described method seems to be the unilateral malignant tumors of the maxillary bone and sinus. This process should not be used on the other hand by bilateral or unilateral tumors where the ethmoid bone, the nasal cavity and the skin are involved.

As far as we know this is the first report about such transconjunctival - transoral approach with preserving the lower orbital rim as a supporting structure of the eye globe after the maxillectomy in comparison to standard approaches. The most important limitation of this study was the small sample of patients, because of the rarity of the pathology in this specific localization. A second limitation is the short follow - up because the approach performed and described is new.

Conclusion

In all cases we performed surgical treatment according to the principles of radicalism. That was proved both by intraoperative and routine pathohistological examination. We succeeded in excluding incisions on the face, as well as avoiding the structural damaging of the superficial muscular-aponeurotic system and the mimic muscles. We also managed to minimize the esthetic defects.

The rehabilitation period of the patients with tumors of facial skeleton in the middle zone of the face, maxilla and zygomatic - orbital complex was reduced. The risks of the inferior eyelid malposition were minimized.

By now all of the patients are observed without relapse and undergone prosthetic rehabilitation [13].

Conflict of Interest Statement

The authors, whose names are listed, certify that they have NO affiliations with or involvement in any organization or entity with any financial interest (such as honoraria, educational grants, participation in speakers' bureaus, membership, employment, consultancies, stock ownership, or other equity interest and expert testimony or patent-licensing arrangements), or non-financial interest (such as personal or professional relationships, affiliations, knowledge or beliefs) in the subject matter or materials discussed in this manuscript.

References

1. Patel SG, Singh B, Polluri A, Bridger PG, Cantu G, et al. (2003) Craniofacial surgery for malignant skull base tumors: report of an international collaborative study. *Cancer* 98: 1179-1187.
2. Atlas of Head and Neck Surgery (2001) Otolaryngology. LLW, pp: 26-32.
3. Shah J (2003) Head and Neck Surgery and Oncology. (3rd edn) Mosby, pp: 57-93.
4. Sisson GA Sr, Toriumi DM, Atiyah RA (1989) Paranasal sinus malignancy: a comprehensive update. *Laryngoscope* 99: 143-150.
5. Liu Z, Yu H, Wang D, Wang J, Sun X, et al. (2013) Combined transoral and endoscopic approach for total maxillectomy: a pioneering report. *J Neurol Surg B Skull Base* 74: 160-165.
6. Ami LP, Chad AZ (2010) Total Maxillectomy. *Operative Tech in Otolaryngo* 21: 166-170.
7. Rivera-Serrano CM, Terre-Falcon R, Duvvuri U (2011) Combined approach for extensive maxillectomy: technique and cadaveric dissection. *Am J Otolaryngol* 32: 417-421.
8. Vural E, Hanna E (2000) Extended lateral rhinotomy incision for total maxillectomy. *Otolaryngol Head Neck Surg* 123: 512-513.
9. Ali AH, Benay Y (2013) Right hemi-maxillectomy via Weber Ferguson approach for the management of squamous cell carcinoma of the maxilla and paranasal sinuses. *Oral Oncology. World Congress of the International Academy of Oral Oncology (IAOO)* 49: 1.
10. deFries HO, Deeb ZE, Hudkins CP (1988) A transfacial approach to the nasal-paranasal cavities and anterior skull base. *Arch Otolaryngol Head Neck Surg* 114: 766-769.
11. Tiwari RM (2001) Transmandibular approach to total maxillectomy. *Indian J Otolaryngol Head Neck Surg* 53: 187-189.
12. Soni R, Jindal S, Singh BP, Mittal N, Chaturvedi TP, et al. (2011) Oral rehabilitation of a patient with sub-total maxillectomy. *Contemp Clin Dent* 2: 63-65.
13. Kawase-Koga Y, Saijo H, Hoshi K, Takato T, Mori Y (2014) Surgical management of odontogenic myxoma: a case report and review of the literature. *BMC Res Notes* 7: 214.